Inflammatory Breast Cancer

This document briefly describes inflammatory breast cancer. For more comprehensive information on this and other types of breast cancer, please refer to our document called *Breast Cancer*.

What is inflammatory breast cancer?

Injury, irritation, or infection can cause increased blood flow and the buildup of white blood cells in the body's tissues. This typically results in redness, warmth, and swelling in the involved parts of the body. This is called inflammation.

Inflammatory breast cancer displays the same symptoms that may occur with inflammation, like swelling, skin redness, and an orange peel like texture of the skin. But this does not mean that IBC (or its symptoms) is caused by infection or injury. The symptoms of IBC are caused by cancer cells blocking lymph vessels in the skin.

Inflammatory breast cancer (IBC) is rare and it differs from other types of breast cancer in its symptoms, prognosis (outlook), and treatment.

There is some disagreement in the numbers, but IBC probably accounts for about 1% of all breast cancers diagnosed in the United States. Some experts believe that IBC may be more common, but diagnosing it is often difficult. This can mean the disease is not being reported as often as it should be.

How is inflammatory breast cancer different from the more common types of breast cancer?

Inflammatory breast cancer causes symptoms that are often different from those of more common breast cancers. It often does not cause a breast lump, and it might not show up on a mammogram. Because it doesn't look like a typical breast cancer, it can be harder to diagnose.

IBC tends to develop at a younger age than the more common form of breast cancer (at an average age 52 versus 57 for non-inflammatory breast cancer). Also, African-

American women appear to be at higher risk of IBC than white women. It also is more common among women who are overweight or obese.

IBC also tends to be more aggressive—it grows and spreads much more quickly— than more common types of breast cancer. Based on the way breast cancer is staged, it is never early stage breast cancer. It is always at least stage IIIB (locally advanced) when it is first diagnosed because the breast cancer cells have grown into the skin. Often, though, it has already spread (metastasized) to distant parts of the body when it is diagnosed, making it stage IV. The advanced stage of IBC, along with the tendency to grow and spread quickly, makes it harder to treat successfully than most other types of breast cancer.

What are the signs and symptoms of inflammatory breast cancer?

Inflammatory breast cancer (IBC) causes a number of signs and symptoms, which most often occur together. These develop quickly and include:

- Breast warmth
- Redness involving more than one-third of the breast
- Thickening (edema/swelling) of the skin of the breast
- The breast may become harder
- Pitting or ridging of the skin of the breast so that it may look like orange peel

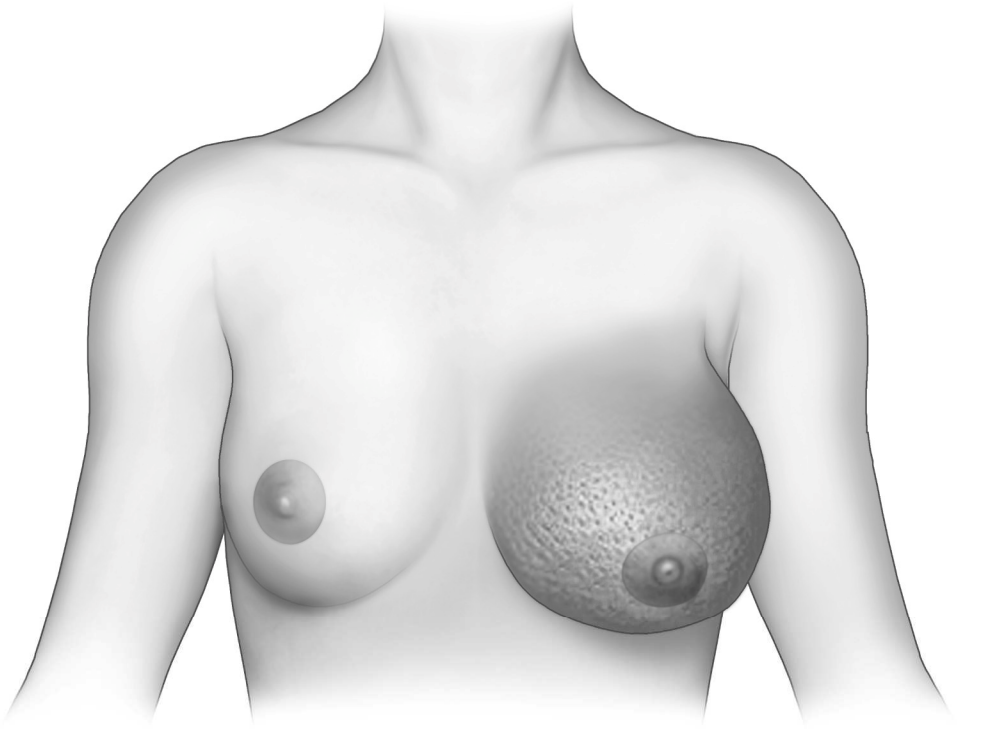

Inflammatory Breast Cancer

Sometimes the nipple becomes inverted, as well. The skin may have the texture of orange peel. Most often, no mass (tumor) can be felt. The skin swelling can cause one breast to appear larger than the other. The breast feels warm to touch and can feel heavy compared to the other breast. The breast may also be tender and painful or itchy.

Tenderness, redness, warmth, and itching are also common symptoms of a breast infection or inflammation (such as mastitis). Because these conditions are much more common than IBC, a doctor might at first suspect infection as a cause and treat with antibiotics. This may be a good first step, but if the symptoms do not get better in 7 to 10 days, tests should be done to look for cancer.

Because IBC grows and spreads so quickly, the cancer may have already spread to nearby lymph nodes by the time the patient notices breast symptoms. This spread can cause lymph nodes under the arm or above the collar bone to become swollen. If the diagnosis is delayed, the cancer can become more advanced, and spread to lymph nodes in the chest or to distant sites.

If you have any of these symptoms, it does not mean that you have IBC, but you should see your doctor right away. If treatment with antibiotics is started you will need to let

your doctor know if this treatment doesn't help, especially if your symptoms worsen or the area affected gets larger. Ask to see a specialist (like a breast surgeon) or get a second opinion if you are concerned.

How can inflammatory breast cancer be detected?

Signs of inflammatory breast cancer (IBC) can be seen on the surface of the skin, and skin thickening often shows up on a mammogram.

Symptoms of IBC can develop very quickly, so women should pay attention to how the skin looks on their breasts and tell their doctors about any changes in skin texture or breast appearance.

In women who are pregnant or breastfeeding, breast redness and swelling is more often caused by an infection (*mastitis*) than by IBC, so doctors might try treatments like antibiotics for a short time first. The possible diagnosis of IBC should be considered more strongly when a woman who is not pregnant or breastfeeding comes in with these symptoms. Breast infection is less common in women who are not pregnant or breastfeeding, and even rarer in women after menopause. When infection occurs it is usually associated with fever or other signs of infection.

Following the American Cancer Society guidelines for early detection of breast cancer can improve a woman's odds of finding most types of breast cancer early, when it can be treated most successfully. Unfortunately, because IBC grows and spreads so fast, screening is not generally helpful for finding this disease early.

(For more information on the American Cancer Society guidelines, see our document called *Breast Cancer: Early Detection*.)

How is inflammatory breast cancer diagnosed?

Imaging tests

If inflammatory breast cancer (IBC) is suspected, the doctor will probably order an imaging test. A diagnostic **mammogram** is usually the first test ordered. Sometimes the swelling and tenderness can make it hard to do a good mammogram. The mammogram may show thickened skin, often without a visible mass (tumor). It can also show that the affected breast is larger and denser than the other breast.

Often a breast **ultrasound** is ordered as well. The ultrasound is often able to show that lymph nodes under the arm are enlarged and may find breast masses (tumors) if they are present. Ultrasound can also be useful in guiding a needle for a biopsy procedure.

MRI (magnetic resonance imaging) can find breast tissue abnormalities if the mammogram result is normal. It can be used to guide a biopsy of those abnormal areas

CT (computed tomography) of the chest, abdomen, and pelvis is sometimes done to look for the spread of cancer.

A **PET** (positron emission tomography) scan is another test that may be useful. This test is often combined with a CT scan. PET/CT can be useful in finding areas of cancer spread to lymph nodes and distant sites.

With IBC it is important to document in detail the condition of the breast (how much redness and swelling is present). In some centers, a photo of the breast is taken to show the amount of redness and swelling before starting treatment. It is ideal to take the photo before breast biopsies because the biopsy itself can cause short-term swelling/bleeding. The doctor can then compare the current exam to the original photo to see how the cancer is responding to treatment.

More information about these tests can be found in our document called *Breast Cancer*.

Biopsy

Breast cancer is diagnosed by a biopsy, removing a sample of the breast tissue and looking at it under the microscope. Your physical exam and other tests may show findings that are "suspicious for" IBC, but only a biopsy can tell for sure that cancer is present.

Breast biopsies can be done in many ways. Samples of breast tissue can be removed using fine needle aspiration (FNA), core needle biopsy, vacuum-assisted biopsy, or open (excisional or incisional) biopsies. The type of biopsy used depends on what area is affected and what it looks like. It also depends on whether a mass (tumor) can be seen on an imaging test (like MRI). A biopsy for IBC often involves a core needle biopsy under ultrasound or MRI guidance. IBC can also be diagnosed with a skin biopsy if no area deeper in the breast is identified on breast imaging.

Tests on biopsy samples

Biopsy samples will be looked at under the microscope to see if cancer is present. The cancer cells will be *graded* based on how abnormal they look. They will also be tested for certain proteins that help decide if certain treatments will be helpful.

Women whose breast cancer cells contain hormone receptors are likely to benefit from treatment with hormone therapy drugs. The cells are tested for the hormone receptors estrogen receptor (ER) and progesterone receptor (PR). If the cancer cells have those receptors they are called ER-positive, PR-positive, or just hormone receptor-positive.

Cancer cells are also tested to see if they contain too much of a protein called HER2/neu (often just called HER2 for short) or too many copies of the gene for that protein. If they do, the cancer is called HER2-positive, and the patient may be helped by certain drugs that target HER2.

More information about biopsy types and the tests done on biopsy sample can be found in the section “How is breast cancer diagnosed?” in our *Breast Cancer* document.

Staging of inflammatory breast cancer

Staging is the process of finding out how widespread a cancer is when it is diagnosed. For breast cancer, staging takes into account certain factors:

- Characteristics of the breast tumor, or T stage
- Spread to nearby lymph nodes, or N stage
- Spread to distant organs and tissues (like the bones or lungs), or M stage

These factors are taken together to make the overall stage of the cancer, which can range from I to IV for breast cancer.

Stages of inflammatory breast cancer

The T stage of a breast cancer can range from T1 to T4, but all inflammatory breast cancers are T4.

N stages range from N1 to N3.The clinical N stage is based on the presence of cancer in lymph nodes on the same side as the breast cancer under the arm (called *axillary lymph nodes*), around the collarbone (called *supraclavicular* or *infraclavicular* lymph nodes), or inside the chest (called *internal mammary lymph nodes*).

M stages are M0 and M1. If the cancer has not spread outside the breast and nearby lymph nodes it is M0. If the cancer has spread it is M1.

Overall stage

Inflammatory breast cancer that has spread outside of the breast and nearby lymph nodes is stage IV.

All other inflammatory breast cancers are stage III. If the cancer has spread to lymph nodes around the collarbone or inside the chest, it is stage IIIC. Otherwise, it is stage IIIB.

More information about staging of breast cancer can be found in the staging section of our document *Breast Cancer*.

Survival rates for inflammatory breast cancer

Survival rates are often used by doctors as a standard way of discussing a person's prognosis (outlook). Some patients with cancer might want to know the survival statistics for people in similar situations, while others may not find the numbers helpful, or may

even not want to know them. If you decide you don’t want to know, stop reading here and skip to the next section.

Median survival is the length of time for half of the patients in a group to have died. By definition, half of the patients in that group are still alive. It is important to remember that the median is just a kind of average used by researchers. No one is "average" and many people have much better outcomes than the median. Also, people with inflammatory breast cancer can die of other things, and these numbers don’t take that into account.

These survival rates are based on people diagnosed years ago. Improvements in treatment since then may result in a more favorable outlook for people now being diagnosed with inflammatory breast cancer.

Survival rates are often based on previous outcomes of large numbers of people who had the disease, but they cannot predict what will happen in any particular person's case. Many other factors can affect a person's outlook, such as age, general health, treatment received, and how well the cancer responds to treatment. Your doctor can tell you how the numbers below may apply to you, as he or she is familiar with your situation.

Inflammatory breast cancer (IBC) is considered an aggressive cancer because it grows quickly, is more likely to have spread at the time it is found, and is more likely to come back after treatment than most other types of breast cancer. The prognosis (outlook) is generally not as good as it is for most other types of breast cancer.

These numbers are based on data from the National Cancer Institute's Surveillance, Epidemiology, and End Results (SEER) database, for patients who were diagnosed with inflammatory breast cancer between 1990 and 2008.

Stage	Median Survival
Stage III	57 months
Stage IV	21 months

How is inflammatory breast cancer treated?

The following is a brief summary of the treatment of inflammatory breast cancer (IBC). For more detailed information on the treatments discussed, see the treatment section of our document called *Breast Cancer*.

Stage III

Inflammatory breast cancer (IBC) that has not spread outside the breast or nearby lymph nodes is stage IIIB or IIIC. The usual treatment is chemotherapy (chemo) to try to shrink the tumor, followed by surgery to remove the cancer. Radiation follows surgery. In some

cases, more chemo may be given after radiation. Combining these 3 types of treatment, starting with systemic chemo that reaches cells throughout the body, followed by local therapy (with surgery and radiation) has improved survival significantly over the years.

Chemo is the use of drugs for treating cancer. The drugs can be swallowed in pill form, or they can be injected by needle into a vein or muscle. Because the drugs enter the bloodstream and circulate throughout the body to reach and destroy cancer cells wherever they are, chemo is considered systemic therapy. It treats both the main tumor as well as any cancer cells that have broken off and spread to lymph nodes or distant organs.

Using chemo before surgery is called *neoadjuvant* or pre-operative treatment. The use of anthracyclines (such as doxorubicin/Adriamycin® and epirubicin/Ellence®) and taxanes (such as paclitaxel/Taxol® and docetaxel/Taxotere®) as chemo drugs for IBC have been shown to improve outcomes. Most women with IBC receive one of each type in some combination (although not always together – they may receive one followed by the other). Other chemo drugs may be used as well.

If the cancer is HER2-positive (the cancer cells have too much of a protein called HER2), the targeted therapy drug called *trastuzumab* (Herceptin®) is given as well. Sometimes the targeted drug pertuzumab (Perjeta) is given as well. These drugs can lead to heart problems when given with an anthracycline, so one option is to give the anthracycline first (without trastuzumab or pertuzumab), followed by treatment with a taxane and trastuzumab (with or without pertuzumab).

If the cancer is hormone-receptor negative and HER2-negative (known as triple negative), the chemo drug carboplatin may be added to paclitaxel.

Participation in a clinical trial of IBC is also a good option because IBC is so rare and these studies can allow access to drugs not available for standard treatment. More information about clinical trials can be found in our document called *Clinical Trials: What You Need To Know*.

If the cancer improves with chemo, surgery is then performed (as long as the cancer has not spread). The standard operation is a modified radical mastectomy, where the entire breast and the lymph nodes under the arm are removed. Because IBC affects so much of the breast and skin, breast conserving surgery (partial mastectomy or lumpectomy) or skin-sparing mastectomy is not a treatment option. It isn't clear that sentinel lymph node biopsy (where only one or a few nodes are removed) is reliable in IBC, so it is also not an option.

Breast reconstruction should be delayed until after the radiation that most often follows surgery. If, after chemo and surgery, no cancer is found in the breast or in the lymph nodes, the patient is far less likely to have the cancer recur (come back later).

If the cancer has not responded to chemo (and the breast is still very swollen and red), surgery cannot be done. Either other chemo drugs will be tried or the breast may be treated with radiation. Then if the cancer responds (the breast shrinks and stops being red), surgery may be an option.

If breast radiation isn't given before surgery, it is given after surgery, even if no cancer is thought to remain. This is called *adjuvant radiation* and lowers the chance that the cancer will come back. Radiation is usually given 5 days a week for 6 weeks, but in some cases a more intense treatment (twice a day) can be used in this disease. Depending on how much tumor was found in the breast after surgery, radiation might be delayed until further chemo is given.

Treatment after surgery and radiation often includes additional systemic treatment. This is known as *adjuvant therapy* and can include chemo, hormonal therapy (tamoxifen or an aromatase inhibitor, if the cancer cells contain hormone receptors), and/or trastuzumab (if the cancer is HER2-positive).

Stage IV

Patients with metastatic disease (Stage IV) are treated with some type of systemic therapy. This may include chemo, hormonal therapy, and/or targeted therapy with a drug that targets HER2 (if the cancer is HER2-positive). This could include trastuzumab (which could be given with pertuzumab, but other targeted drugs can also be used, such as ado-trastuzumab emtansine (TDM-1, Kadcyla®).

If you'd like more information on a drug used in your treatment or a specific drug mentioned in this section, see our Guide to Cancer Drugs , or call us with the names of the medicines you're taking.

What's new in inflammatory breast cancer research?

Because inflammatory breast cancer (IBC) is rare, it is hard for researchers to find women to study and learn the best treatments for it. But there have been some recent advances in understanding and treating IBC.

Studies have shown that over the past couple of decades, IBC has become more common, while other forms of locally advanced breast cancer have become less common. Researchers are still not sure why this has happened.

Studies comparing DNA and other molecules from IBC with that of the usual types of breast cancer have shown some important differences. Scientists believe that some of these differences account for the unique and aggressive way that IBC spreads and grows. They are hopeful that understanding these differences will lead to more effective treatments that target molecules specific to IBC.

Clinical studies during the past decade have shown doctors how to modify the usual breast cancer treatments (chemotherapy, radiation, hormonal therapy, and surgery) so that they are best suited for women with IBC. For example, studies have shown the value of using chemotherapy as the first treatment, before surgery or radiation.

Chemotherapy

Studies are looking at different chemotherapy combinations to treat inflammatory breast cancer, such as epirubicin (Ellence®), albumin-bound paclitaxel (Abraxane®), and gemcitabine (Gemzar®).

Targeted therapy

Targeted therapy is a newer type of cancer treatment that uses drugs or other substances to identify and attack cancer cells while doing little damage to normal cells. These therapies attack the cancer cells' inner workings—the programming that makes them different from normal, healthy cells. Each type of targeted therapy works differently, but all alter the way a cancer cell grows, divides, repairs itself, or interacts with other cells. Targeted drugs work differently from standard chemo drugs and often have different (and less severe) side effects.

Drugs for HER2-positive cancer

One study has shown that the targeted drug lapatinib (Tykerb) can be a useful treatment for IBC in women whose disease has stopped responding to regular chemo plus trastuzumab. In this study the lapatinib was given alone, without other chemo drugs. It caused the tumors to shrink in many of the women treated. This drug is also being studied with chemo before surgery.

Other drugs that target HER2 are also being studied, such as afatinib.

Other targeted drugs

Clinical trials are also looking at other targeted therapy drugs (besides those targeting HER2) in the treatment of inflammatory breast cancer. Some of the drugs being tested include dovitinib and pazopanib.

If you'd like more information on a drug used in your treatment or a specific drug mentioned in this section, see our Guide to Cancer Drugs , or call us with the names of the medicines you're taking.

Where can I find more information about inflammatory breast cancer?

Inflammatory Breast Cancer Research Foundation
Telephone: 877-786-7422
Website: www.ibcresearch.org

For more information about breast cancer, please see our documents called *Breast Cancer* and *Breast Cancer: Early Detection*.

References: inflammatory breast cancer

Dawood S, Cristofanilli M. Inflammatory breast cancer: what progress have we made? *Oncology* (Williston Park). 2011 Mar;25(3):264−270, 273.

Dawood S, Cristofanilli M. What progress have we made in managing inflammatory breast cancer? *Oncology*. 2007;21:673−679

Dawood S, Merajver SD, Viens P, et al. International expert panel on inflammatory breast cancer: consensus statement for standardized diagnosis and treatment. *Ann Oncol*. 2011 Mar;22(3):515−523.

Hance KW, Anderson WF, Devesa SS, Young HA, Levine PH. Trends in inflammatory breast carcinoma incidence and survival: the Surveillance, Epidemiology, and End Results program at the National Cancer Institute. *J Natl Cancer Inst*. 2005;97:966−975.

Hennessy BT, Gonzalez-Angulo AM, Hortobagyi GN, et al. Disease-free and overall survival after pathologic complete disease remission of cytologically proven inflammatory breast carcinoma axillary lymph node metastases after primary systemic chemotherapy. *Cancer*. 2006;106:1000−1006.

Howlader N, Noone AM, Krapcho M, et al (eds). SEER Cancer Statistics Review, 1975-2009 (Vintage 2009 Populations), National Cancer Institute. Bethesda, MD, http://seer.cancer.gov/csr/1975_2009_pops09/, based on November 2011 SEER data submission, posted to the SEER web site, April 2012.

Kaufman B, Trudeau M, Awada A, et al. Lapatinib monotherapy in patients with HER2-overexpressing relapsed or refractory inflammatory breast cancer: final results and survival of the expanded HER2+ cohort in EGF103009, a phase II study. *Lancet Oncol*. 2009;10:581−588.

National Comprehensive Cancer Network (NCCN). NCCN Clinical Practice Guidelines in Oncology. *Breast Cancer.* Version 3.2014. Accessed at www.nccn.org on June 10, 2014.

Panades M, Olivotto IA, Speers CH, et al. Evolving treatment strategies for inflammatory breast cancer: a population based survival analysis. *J Clin Oncol*. 2005;23:1941−1950.

Schlichting JA, Soliman AS, Schairer C, Schottenfeld D, Merajver SD. Inflammatory and non-inflammatory breast cancer survival by socioeconomic position in the Surveillance, Epidemiology, and End Results database, 1990-2008. *Breast Cancer Res Treat*. 2012 Aug;134(3):1257-68. Epub 2012 Jun 26.

Sinclair S, Swain SM. Primary systemic chemotherapy for inflammatory breast cancer. *Cancer*. 2010 Jun 1;116(11 Suppl):2821−2828.

Yang WT, Le-Petross HT, Macapinlac H, Carkaci S, Gonzalez-Angulo AM, Dawood S, Resetkova E, Hortobagyi GN, Cristofanilli M: Inflammatory breast cancer: PET/CT, MRI, mammography and sonography findings. *Breast Cancer Res Treat*. 2008 Jun;109(3):417-26. Epub 2007 Jul 26. Review

Last Medical Review: 8/28/2014
Last Revised: 6/10/2015

2014 Copyright American Cancer Society

For additional assistance please contact your American Cancer Society
1-800-227-2345 or www.cancer.org