Style Definition: Table 2: Space Before: 0 pt, After: 3 pt, No widow/orphan control, Don't hyphenate

Mammograms and Other Breast Imaging Tests

Mammogram basics

What is a mammogram?

A mammogram is an x-ray of the breast.

Why do I need mammograms?

A mammogram can often find or detect breast cancer early, when it's small and even before a lump can be felt. This is when it's easiest to treat.

What are the types of mammograms?

Screening Mammograms

A *screening mammogram* is used to look for signs of breast cancer in women who don't have any breast symptoms or problems. X-ray pictures of each breast are taken from 2 different angles.

Diagnostic Mammograms

Mammograms can also be used to look at a woman's breast if she has a breast problem or a change is seen on a screening mammogram. When used in this way, they are called *diagnostic mammograms*. They may include extra views (images) of the breast that aren't part of screening mammograms. Sometimes diagnostic mammograms are used to screen women who were treated for breast cancer in the past.

What do mammograms show?

Mammograms can't prove that an abnormal area is cancer, but they can help health care providers decide whether more testing is needed. The 2 main types of breast changes found with a mammogram are calcifications and masses.

Calcifications are tiny mineral deposits within the breast tissue. They look like small white spots on the pictures. They may or may not be caused by cancer.

A **mass**, or tumor, may or may not have calcifications, and is another important change seen on mammograms. Masses can be many things, including cysts (fluid-filled sacs) and non-cancerous solid tumors, but they could also be cancer. Any mass that's not clearly a simple fluid-filled cyst usually needs to be biopsied. (A biopsy is taking out a small piece of tissue to see if cancer cells are in it.)

Having your prior mammograms available for the radiologist is very important. They can help to show if a mass or calcification has changed over time, which could affect whether a biopsy is needed.

How do mammograms work?

A mammogram uses a machine designed to look only at breast tissue. The machine takes x-rays at lower doses than usual x-rays. Because these x-rays don't go through tissue easily, the machine has 2 plates that compress or flatten the breast to spread the tissue apart. This gives a better picture and allows less radiation to be used.

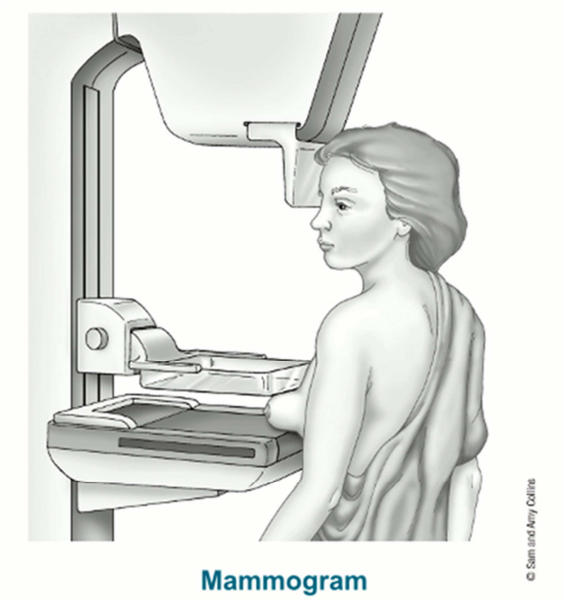

A **digital mammogram** (also known as *full-field digital mammography* or FFDM) is like a standard mammogram in that x-rays are used to make pictures of the breast. The differences are in the way the picture is made, looked at, and stored. Standard mammograms are printed on large sheets of film. Digital images are recorded and saved as files in a computer. Digital mammograms are becoming more widely available. They may be better than standard film mammograms for some women, but they're not clearly better for everyone. Women should not skip their regular mammogram because a digital one isn't available.

A newer type of mammogram is known as *breast tomosynthesis* or **3D mammography**. For this, the breast is compressed once and a machine takes many low-dose x-rays as it moves over the breast. A computer then puts the images together into a 3-dimensional picture. This uses more radiation than most standard 2-view mammograms, but it may allow doctors to see the breast tissues more clearly. Some studies have suggested it might lower the chance of being called back for follow-up testing. It may also be able to find more cancers. But not all health insurances cover tomosynthesis.

Are mammograms safe?

The benefits of mammography outweigh any possible harm from the radiation exposure. Modern machines use low radiation doses to get breast x-rays that are high in image

quality. On average the total dose for a typical mammogram with 2 views of each breast is about 0.4 mSv. (A mSv is a measure of radiation dose.)

To put dose into perspective, people in the US are normally exposed to an average of about 3 mSv of radiation each year just from their natural surroundings. (This is called background radiation.) The dose of radiation used for a screening mammogram of both breasts is about the same amount of radiation a woman would get from her natural surroundings over about 7 weeks.

If there's any chance you might be pregnant, let your health care provider and x-ray technologist know. Although the risk to the fetus is likely very small, screening mammograms aren't routinely done in pregnant women.

Mammograms: What to know before you go

A mammogram is an important step in taking care of yourself and your breasts. Whether you're a mammogram newbie or a veteran, knowing what to expect may help the process go more smoothly.

How to prepare for your mammogram

- If you have a choice, use a facility that specializes in mammograms and does many mammograms a day.
- Try to go to the same facility every time so that your mammograms can easily be compared from year to year.
- If you're going to a facility for the first time, bring a list of the places and dates of mammograms, biopsies, or other breast treatments you've had before.
- If you've had mammograms at another facility, try to get those records to bring with you to the new facility (or have them sent there) so the old pictures can be compared to the new ones.
- Schedule your mammogram when your breasts are not tender or swollen to help reduce discomfort and get good pictures. Try to avoid the week just before your period.
- On the day of the exam, don't wear deodorant or antiperspirant. Some of these contain substances that can show up on the x-ray as white spots. If you're not going home afterwards, you may want to take your deodorant with you to put on after your exam.
- You might find it easier to wear a skirt or pants, so that you'll only need to remove your top and bra for the mammogram.

- Discuss any new findings or problems in your breasts with your health care provider before getting the mammogram.

Don’t be afraid of mammograms! Remember that only 2 to 4 screening mammograms in 1,000 lead to a diagnosis of breast cancer.

Tips for getting a mammogram

These tips can help you have a good quality mammogram:

- Always describe any breast changes or problems you’re having to the technologist doing the mammogram. Also describe any medical history that could affect your breast cancer risk—such as surgery, hormone use, breast cancer in your family, or if you’ve had breast cancer before.
- Before getting any type of imaging test, tell the technologist if you’re breastfeeding or if you think you might be pregnant.

What to expect when getting a screening mammogram

- You’ll have to undress above the waist to get a mammogram. The facility will give you a wrap to wear.
- A technologist will position your breasts for the mammogram. You and the technologist are the only ones in the room during the mammogram.
- To get a high-quality picture, your breast must be flattened. The technologist places your breast on the machine’s plate. The plastic upper plate is lowered to compress your breast for a few seconds while the technologist takes a picture.
- The whole procedure takes about 20 minutes. The actual breast compression only lasts a few seconds.
- You might feel some discomfort when your breasts are compressed, and for some women it can be painful. Tell the technologist if it hurts.
- Two views of each breast are taken for a screening mammogram. But for some women, such as those with breast implants or large breasts, more pictures may be needed.

What to expect when getting a diagnostic mammogram

- More pictures are taken during a diagnostic mammogram with a focus on the area that looked different on the screening mammogram.

- During a diagnostic mammogram, the images are checked by the radiologist while you're there so that more pictures can be taken if needed to look more closely at any area of concern.
- In some cases, special images known as spot views or magnification views are used to make a small area of concern easier to see.

How will I get my mammogram results?

If you don't hear from your health care provider within 10 days, do not assume that your mammogram was normal; call your provider or the facility where the mammogram was done.

A full report of the results of your mammogram will be sent to your health care provider. Mammography clinics also must mail women an easy-to-understand summary of their mammogram results within 30 days—or "as quickly as possible" if the results suggest cancer is present. This means you could get the results before your provider calls you. If you want the full written mammogram report as well as the summary, you'll need to ask for it. We can help you learn more about how to understand your mammogram report.

What does the doctor look for on a mammogram?

A radiologist will look at your mammogram. Radiologists are doctors who diagnose diseases and injuries using imaging tests such as x-rays and CT scans. When possible, the doctor reading your mammogram will compare it to your old mammograms. This helps find small changes that could be signs of cancer.

Here are some of the changes the doctor will look for:

Calcifications

Calcifications are tiny mineral deposits within the breast tissue. They look like small white spots on a mammogram. They may or may not be caused by cancer. There are 2 types of calcifications.

- **Macrocalcifications** are coarse, bigger calcium deposits that are most likely due to changes caused by aging of the breast arteries, old injuries, or inflammation. These deposits are related to non-cancerous conditions and don't need to be checked with a biopsy. Macrocalcifications are found in about half of women over age 50 and in 1 of 10 women under age 50.

- **Microcalcifications** are tiny specks of calcium in the breast. Microcalcifications seen on a mammogram are of more concern than macrocalcifications, but they don't always mean that cancer is present. The shape and layout of microcalcifications help the radiologist judge how likely it is that the change is due to cancer. In most cases, microcalcifications don't need to be checked with a biopsy. But if they have a suspicious look and pattern, a biopsy will be recommended. (During a biopsy, the doctor removes a small piece of the suspicious area to be checked under a microscope. A biopsy is the only way to tell if cancer is really present.)

A mass

A mass is the same as a lump or a tumor. With or without calcifications, it's another important change seen on a mammogram. Masses are areas that look abnormal and they can be many things, including cysts (non-cancerous, fluid-filled sacs) and non-cancerous solid tumors (such as fibroadenomas), but they may also be a sign of cancer.

Cysts can be simple fluid-filled sacs (known as *simple* cysts) or can be partially solid (known as *complex cystic and solid masses*). Simple cysts are not cancer and don't need to be checked with a biopsy. If a mass is not a simple cyst, it's of more concern and a biopsy might be needed to be sure it isn't cancer.

- A cyst and a tumor can feel the same. They can also look the same on a mammogram. The doctor must be sure it's a cyst to know it's not cancer. To be sure that a mass is really a cyst, a breast ultrasound is often done. Another option is to remove (aspirate) the fluid from the cyst with a thin, hollow needle.

- If a mass is not a simple cyst (that is, if it's at least partly solid), more imaging tests may be needed to decide if it might be cancer. Some masses can be watched with regular mammograms or ultrasound to see if they change, but others may need to be checked with a biopsy. The size, shape, and margins (edges) of the mass may help the radiologist decide how likely it is to be cancer.

Having your old mammograms available for the radiologist is very important. They can help show that a mass or calcification has not changed for many years. This would mean that it's likely not cancer and a biopsy isn't needed.

Breast density

Your mammogram report will also contain an assessment of breast density. Breast density is based on how fibrous and glandular tissues are distributed in your breast, vs. how much of your breast is made up fatty tissue.

Dense breasts are not abnormal, but they are linked to a higher risk of breast cancer. We know that dense breast tissue can make it harder to find cancers on a mammogram. Still experts don't agree what other tests, if any, should be done along with mammograms in

women with dense breasts who aren't in a high breast cancer risk group (based on gene mutations, breast cancer in the family, or other factors).

Getting called back after a mammogram

Getting called back after a screening mammogram is fairly common and doesn't mean you have cancer. In fact, less than 10% of women called back for more tests are found to have breast cancer. Often, it just means more pictures or an ultrasound needs to be done to get a closer look at an area of concern. Getting called back is more common after a first mammogram (or when there's no previous mammogram to look at) and after mammograms done in women who haven't gone through menopause.

What else could it be?

You could be called back after your mammogram because:

- The pictures weren't clear or missed some of your breast tissue and need to be retaken.
- You have dense breast tissue or a cyst.
- The radiologist might have seen calcifications or a mass.
- Sometimes an area just looks different from other parts of the breast.

Sometimes when more pictures are taken of the area or mass, or the area is compressed more, it no longer looks suspicious. In fact, most repeat mammograms do not find cancer.

What will happen at the follow-up appointment?

- You're likely to have another mammogram called a diagnostic mammogram. (Your previous mammogram was called a screening mammogram.) A diagnostic mammogram is done just like a screening mammogram, but for a different reason. More pictures are taken during a diagnostic mammogram so that any areas of concern can be carefully studied. A radiologist is on hand to advise the technician (the person who operates the mammogram machine) to be sure they have all the images that are needed.
- You may also have an ultrasound test that uses sound waves to make a computer image of the tissues inside your breast at the area of concern.
- Some women may need a breast MRI. For a breast MRI, you'll lie face down inside a narrow tube for up to an hour while the machine creates more detailed images of the breast tissues. MRI is painless, but can be uncomfortable for people who don't like small, tight spaces.

You can expect to learn the results of your tests during the visit. You are likely to be told 1 of 3 things:

- The suspicious area turned out to be nothing to worry about and you can return to having yearly mammograms.
- The area is probably nothing to worry about, but you should have your next mammogram sooner than 1 year – usually in 4 to 6 months – to watch it closely and make sure it doesn't change over time.
- The changed area could be cancer and a biopsy is needed to know for sure.

You'll also get a letter with a summary of the findings that will tell you if you need more tests and/or when you should schedule your next mammogram.

What if I need a biopsy?

Even if you need a breast biopsy, it still doesn't mean you have cancer. Most biopsy results are not cancer, but a biopsy is the only way to find out. During a biopsy, a small piece of tissue is removed and checked under a microscope.

There are several different types of biopsies – some use a needle and some use a cut in the skin. The type you have depends on things like how suspicious the tumor looks, how big it is, where it is in the breast, how many tumors there are, other medical problems you might have, and your personal preferences.

How can I stay calm while waiting?

Waiting for appointments and the results of tests can be frightening. Many women have strong emotions including disbelief, anxiety, fear, anger, and sadness during this time. Here are some things to remember:

- It's normal to have these feelings.
- Most breast changes are not cancer and are not life-threatening.
- Talking with a loved one or a counselor about your feelings may help.
- Talking with other women who have been through a breast biopsy may help.
- The American Cancer Society is available at 1-800-227-2345 around the clock to answer your questions and provide support.

What if it’s cancer?

If you do have cancer and you’re referred to a breast specialist, use these tips to make your appointment as useful as possible:

- Make a list of questions to ask. Download a list from the American Cancer Society or call us at 1-800-227-2345.
- Take a family member or friend with you. They can serve as an extra pair of ears, take notes, help you remember things later, and give you support.
- Ask if you can record the conversations.
- Take notes. If someone uses a word you don’t know, ask them to spell it and explain it.
- Ask the doctors or nurses to explain anything you don’t understand.

Understanding your mammogram report

The radiologist who reviews your mammogram will categorize your results using a number system of 0 through 6. You should talk to your doctor about the category your results are put into and what you need to do next.

What is a BI-RADS score?

Doctors use a standard system to describe mammogram findings and results. This system (called the Breast Imaging Reporting and Data System or BI-RADS) sorts the results into categories numbered 0 through 6.

By sorting the results into these categories, doctors all over the country can describe what they find on a mammogram using the same words and terms. This makes accurately communicating about these test results and following up after the tests much easier.

What do the BI-RADS scores mean?

Category	Definition	What it means
0	Additional imaging evaluation and/or comparison to prior mammograms is needed.	This means the radiologist may have seen a possible abnormality, but it was not clear and you will need more tests, such as the use of spot compression (applying compression to a smaller area when doing the mammogram), magnified views, special mammogram views, or ultrasound. This may also suggest that your doctor should compare your new mammogram with older ones to see if there have been changes in the area over time.
1	Negative	There's no significant abnormality to report. Your breasts look the same (they are symmetrical) with no masses (lumps), distorted structures, or suspicious calcifications. In this case, negative means nothing bad was found.
2	Benign (non-cancerous) finding	This is also a negative mammogram result (there's no sign of cancer), but the reporting doctor chooses to describe a finding known to be benign, such as benign calcifications, lymph nodes in the breast, or calcified fibroadenomas. This ensures that others who look at the mammogram will not misinterpret the benign finding as suspicious. This finding is recorded in your mammogram report to help when

		comparing to future mammograms.
3	Probably benign finding – Follow-up in a short time frame is suggested	The findings in this category have a very high chance (greater than 98%) of being benign (not cancer). The findings are not expected to change over time. But since it's not proven benign, it's helpful to see if the area in question does change over time. You will likely need follow-up with repeat imaging in 6 months and regularly after that until the finding is known to be stable (usually at least 2 years). This approach helps avoid unnecessary biopsies, but if the area does change over time, it still allows for early diagnosis.
4	Suspicious abnormality – Biopsy should be considered	Findings do not definitely look like cancer but could be cancer. The radiologist is concerned enough to recommend a biopsy. The findings in this category can have a wide range of suspicion levels. For this reason, some, but not all, doctors divide this category further: 4A: Finding with a low suspicion of being cancer 4B: Finding with an intermediate suspicion of being cancer 4C: Finding of moderate concern of being cancer, but not as high as Category 5
5	Highly suggestive of	The findings look like cancer and have a high

	malignancy – Appropriate action should be taken	chance (at least 95%) of being cancer. Biopsy is very strongly recommended.
6	Known biopsy-proven malignancy – Appropriate action should be taken	This category is only used for findings on a mammogram that have already been shown to be cancer by a previous biopsy. Mammograms may be used in this way to see how well the cancer is responding to treatment.

X-ray assessment is incomplete

Category 0: Additional imaging evaluation and/or comparison to prior mammograms is needed.

This means a possible abnormality may not be clearly seen or defined and you will need more tests, such as the use of spot compression (applying compression to a smaller area when doing the mammogram), magnified views, special mammogram views, or ultrasound.

This may also suggest that the mammogram should be compared with older ones to see if there have been changes in the area over time.

X-ray assessment is complete

Category 1: Negative

There's no significant abnormality to report. The breasts look the same (they are symmetrical) with no masses (lumps), distorted structures, or suspicious calcifications. In this case, negative means nothing bad was found.

Category 2: Benign (non-cancerous) finding

This is also a negative mammogram result (there's no sign of cancer), but the reporting doctor chooses to describe a finding known to be benign, such as benign calcifications, lymph nodes in the breast, or calcified fibroadenomas. This ensures that others who look at the mammogram will not misinterpret the benign finding as suspicious. This finding is recorded in the mammogram report to help when comparing to future mammograms.

Category 3: Probably benign finding – Follow-up in a short time frame is suggested

The findings in this category have a very high chance (greater than 98%) of being benign (not cancer). The findings are not expected to change over time. But since it's not proven benign, it's helpful to see if the area in question does change over time.

Follow-up with repeat imaging is usually done in 6 months and regularly after that until the finding is known to be stable (usually at least 2 years). This approach helps avoid unnecessary biopsies, but if the area does change over time, it still allows for early diagnosis.

Category 4: Suspicious abnormality – Biopsy should be considered

Findings do not definitely look like cancer but could be cancer. The radiologist is concerned enough to recommend a biopsy. The findings in this category can have a wide range of suspicion levels. For this reason, some, but not all, doctors divide this category further:

- **4A:** Finding with a low suspicion of being cancer
- **4B:** Finding with an intermediate suspicion of being cancer
- **4C:** Finding of moderate concern of being cancer, but not as high as Category 5

Category 5: Highly suggestive of malignancy – Appropriate action should be taken

The findings look like cancer and have a high chance (at least 95%) of being cancer. Biopsy is very strongly recommended.

Category 6: Known biopsy-proven malignancy – Appropriate action should be taken

This category is only used for findings on a mammogram that have already been shown to be cancer by a previous biopsy. Mammograms may be used in this way to see how well the cancer is responding to treatment.

BI-RADS reporting breast density

Your mammogram report will also include an assessment of your breast density. BI-RADS classifies breast density into 4 groups:

- **The breasts are almost entirely fatty** – The breasts contain little fibrous and glandular tissue, which means the mammogram would likely detect anything abnormal.
- **There are scattered areas of fibroglandular density** – There are a few areas of fibrous and glandular tissue in the breast.
- **The breasts are heterogeneously dense, which may obscure small masses** – The breast has more areas of fibrous and glandular tissue that are found throughout the breast. This can make it hard to see small masses.
- **The breasts are extremely dense, which lowers the sensitivity of mammography** – The breast has a lot of fibrous and glandular tissue. This may make it harder to find a cancer that may be present, as it can blend in with normal breast tissue.

In some states, women whose mammograms show heterogeneously dense or extremely dense breasts must be told that they have "dense breasts" in the summary of the mammogram report that is sent to patients (sometimes called the lay summary). The language used is mandated by law, and may say something like:

"Your mammogram shows that your breast tissue is dense. Dense breast tissue is common and is not abnormal. However, dense breast tissue can make it harder to evaluate the results of your mammogram and may also be associated with an increased risk of breast cancer. This information about the results of your mammogram is given to you so you will be informed when you talk with your doctor. Together, you can decide which screening options are right for you. A report of your results was sent to your primary physician."

What are the limitations of mammograms?

Mammograms are the best breast cancer screening tests we have at this time. But mammography has limitations. A false-negative mammogram looks normal even though breast cancer is present. A false-positive mammogram looks abnormal but there's no cancer in the breast.

The value of a screening mammogram depends on a woman's overall health status. Finding breast cancer early may not help her live longer if she has other kinds of serious or life-threatening health problems, such as congestive heart failure (CHF), end-stage renal disease, or chronic obstructive pulmonary (lung) disease (COPD). The American Cancer Society screening guidelines emphasize that women with serious health problems or short life expectancies should discuss with their doctors whether they should continue having mammograms. Our guidelines also stress that age alone should not be the reason to stop having regular mammograms.

It’s important to know that even though mammograms can show breast cancers that are too small to be felt, treating a small tumor does not always mean it can be cured. A fast-growing or aggressive cancer might have already spread.

False-negative results

- A false-negative mammogram looks normal even though breast cancer is present. Overall, screening mammograms do not find about 1 in 5 breast cancers.
- Women with dense breasts have more false-negative results. Breasts often become less dense as women age, so false negatives are more common in younger women.

False-positive results

- A false-positive mammogram looks abnormal but no cancer is actually present. Abnormal mammograms require extra testing (diagnostic mammograms, ultrasound, and sometimes MRI or even biopsy) to find out if the change is cancer.
- False-positive results are more common in women who are younger, have dense breasts, have had breast biopsies, have breast cancer in the family, or are taking estrogen.
- About half of the women getting annual mammograms over a 10-year period will have a false-positive finding. The odds of a false-positive finding are highest for the first mammogram. Women who have past mammograms available for comparison reduce their odds of a false-positive finding by about 50%.
- False-positive mammograms can cause anxiety. The extra tests needed to be sure cancer isn’t there cost time and money and maybe even physical discomfort.

Over-diagnosis and over-treatment

Screening mammograms can find invasive breast cancer and ductal carcinoma in situ (DCIS, cancer cells in the lining of breast ducts) that need to be treated. But it’s possible that some of the invasive cancers and DCIS found would not grow or spread. (Finding and treating cancers that would never cause problems is called over-diagnosis.) This means that some cancers are not life-threatening, and never would have been found or treated if the woman had not gotten a mammogram. The problem is that doctors can’t tell these cancers from those that will grow and spread.

Over diagnosis leads to some women getting treatment that’s not really needed. We don’t know which women fall into this group when the cancer is found because we can’t tell which cancers will be life-threatening and which won’t ever cause problems. Treating

women with cancers that would never cause problems would be considered over-treatment.

Because doctors often can't be sure which cancers and cases of DCIS will become life-threatening, all cases are treated. It exposes these women to the adverse effects of cancer treatment that's really not needed.

Still, over-diagnosis is not that common. There's a wide range of estimates of the percentage of breast cancers that might be over-diagnosed by mammography, but the most credible estimates range from 0-10%.

Having a mammogram after you've had breast cancer surgery

There are many different kinds of breast cancer surgery, and the type of surgery you have had will determine whether you need to get mammograms in the future. If you have had breast-conserving surgery, you need to continue to get mammograms. If you have had a mastectomy, you may not need a mammogram.

Regardless of what breast cancer surgery you have had, you will still need to get mammograms of the unaffected breast. This is very important, because women who have had one breast cancer are at higher risk of developing a new cancer in the other breast.

While the American Cancer Society does not have specific recommendations or guidelines for mammograms or other breast imaging in women who have been treated for breast cancer, there is information available about what these women will likely need to do.

Mammograms after breast-conserving surgery

Most experts recommend that women who have had breast-conserving surgery or BCS (sometimes called a partial mastectomy or lumpectomy) get a mammogram of the treated breast 6 months after radiation treatment ends. Radiation and surgery both cause changes in the skin and breast tissues that will show up on the mammogram, making it harder to read. The changes usually show up best about 6 months after the radiation ends, and the mammogram done at this time serves as a new baseline for the affected breast. Future mammograms will be compared with this one, to help the doctor check on healing and look for signs that the cancer has come back (recurred).

Depending on the results, the next mammogram for that breast may be 6 to 12 months later. Follow-up mammograms of the treated breast should be done at least yearly after that, but some doctors may recommend that you have mammograms more often. Routine mammograms will still need to be done on the opposite (untreated) breast.

Mammograms after mastectomy

Women who have had a mastectomy (including *simple mastectomy*, *modified radical mastectomy*, and *radical mastectomy*) to treat breast cancer need no further routine screening mammograms on the affected side. If both breasts are removed, they don't need mammograms at all. There isn't enough tissue remaining after these kinds of mastectomies to do a mammogram. Cancer can come back in the skin or chest wall on that side, but it can be found on a physical exam.

It's possible for women with reconstructed breasts to get mammograms, but experts agree that women who have breast reconstruction after a simple, modified radical mastectomy, or radical mastectomy don't need routine mammograms. Still, if an area of concern is found during a physical exam on a woman who has had breast reconstruction, a diagnostic mammogram may be done. Ultrasound or MRI may also be used to look at the area closely.

Women who have had a *subcutaneous mastectomy*, also called skin-sparing mastectomy, still need follow-up mammograms. In this surgery, the woman keeps her nipple and the tissue just under the skin. Often, an implant is put under the skin. This surgery leaves behind enough breast tissue to require yearly screening mammograms in these women.

Any woman who's not sure what type of mastectomy she has had or whether she needs to get mammograms should ask her doctor.

Mammograms for women with breast implants

If you have breast implants, you should still get regular screening mammograms. However, if you have implants, you need to tell the technologist before starting the mammogram and you should also be aware that it may be hard for the doctor to see certain parts of your breast.

The x-rays used in mammograms cannot go through silicone or saline implants well enough to show the breast tissue under them. This means that the part of the breast tissue covered by the implant won't be seen on the mammogram.

Very rarely, mammograms can rupture an implant. It's important to tell the technologist you have implants before your mammogram is started. In fact, it's best to mention this when you make the appointment to have your mammogram done. This way you can find out if the facility has experience doing mammograms in women with breast implants.

So the doctor can see as much breast tissue as possible, women with implants have 4 extra pictures done (2 on each breast), as well as the 4 standard pictures taken during a screening mammogram. In these extra pictures, called *implant displacement* (ID) views,

the implant is pushed back against the chest wall and the breast is pulled forward over it. This allows better imaging of the front part of each breast.

Implant displacement views are more difficult to do and can be uncomfortable in women who have had hard scar tissue form around the implants (called *contractures*). They're easier in women whose implants are placed underneath (behind) the chest muscles.

Breast ultrasound

Breast ultrasound is often used to examine a breast change that's seen on a mammogram.

Why is breast ultrasound used?

Ultrasound is useful for looking at some breast changes, such as those that can be felt but not seen on a mammogram or changes in women with dense breast tissue. It also can be used to look at a change that may have been seen on a mammogram. Ultrasound can be used to tell the difference between fluid-filled cysts and solid masses. (If a lump is really a cyst, it's not cancer.)

Ultrasound can be used to help guide a biopsy needle into an area of change so cells can be taken out and tested for cancer. It can also be used to look for and guide a biopsy needle into swollen lymph nodes under the arm.

Ultrasound is widely available, easy to have done, and costs less than a lot of other options.

How is it done?

Breast ultrasound uses sound waves to make a computer picture of the inside of the breast.

A gel is put on the skin of the breast and an instrument called a transducer is moved across the skin to show the underlying tissue structure. The transducer sends out sound waves and picks up the echoes as they bounce off body tissues. The echoes are made into a black and white image on a computer screen. This test is painless and does not use radiation.

As with any breast imaging, breast ultrasound depends on the level of skill and experience of the doctor interpreting the images. When a handheld transducer is used, ultrasound is also dependent on the skill and experience of the person doing the scan.

Automated ultrasound is an option that uses a much larger transducer to take hundreds of images that cover nearly the entire breast. When automated ultrasound is used, a second handheld ultrasound is often needed to get more pictures of suspicious areas.

Breast MRI (magnetic resonance imaging)

Although MRI can find some cancers not seen on a mammogram, it's also more likely to find something that turns out not to be cancer (called a false positive). False-positive findings have to be checked out to know that cancer isn't present. This means more tests and/or biopsies. This is why MRI is not recommended as a screening test for women at average risk of breast cancer, because it would mean unneeded biopsies and other tests for many of these women.

What you need to know about getting a breast MRI

Just as mammograms are done using x-ray machines specially designed for the breasts, breast MRI also requires special equipment. This MRI machine is called an *MRI with dedicated breast coils*. Not all hospitals and imaging centers have dedicated breast MRI equipment. It's important to have your screening MRI at a facility with dedicated equipment that can do an MRI-guided breast biopsy. Otherwise, if a biopsy is needed, the MRI will need to be repeated at another facility.

MRI uses strong magnets instead of radiation to make very detailed, cross-sectional pictures of the body. An MRI scan takes pictures from many angles, as if someone were looking at a slice of your body from the front, from the side, or from above your head. MRI creates pictures of soft tissue parts of the body that are sometimes hard to see using other imaging tests.

Tips for getting ready for the test

Check with your insurance company before getting an MRI: Breast MRI costs a lot, and may need to be approved by your insurance company before the scan is done. Most private insurance plans that pay for mammogram screening also pay for MRI as a screening test if a woman can be shown to be at high risk. It might help to go to a center with a high-risk clinic, where the staff has experience getting approval for breast MRIs.

Follow all instructions: You don't usually need a special diet or preparation before an MRI, but follow any instructions you're given.

If you have trouble with enclosed spaces: If being in an enclosed space is a problem for you (you have claustrophobia), you might need to take medicine to help you relax while in the scanner. Talking with the technologist or a patient counselor, or getting a tour of the MRI machine before the test can help. You'll be in the exam room alone, but you can talk to the MR technologist, who can see and hear what's going on. In some cases, you may be able to have the test done with an *open MRI* machine that allows more space around your body.

Remove metal objects: Before the test, you will be asked to undress and put on a gown or other clothes without zippers or metal. Be sure to remove any metal objects you can, like hair clips, jewelry, dental work, and body piercings.

If you have metal in your body: Before the scan, the technologist will ask you if you have any metal in your body. Some metallic objects will not cause problems, but others can.

If you have implants: If you have any of these types of implants, you should not even enter the MRI scanning area unless told to do so by a radiologist or technologist who knows you have:

- An implanted defibrillator or pacemaker
- Clips used on a brain aneurysm
- A cochlear (ear) implant
- Metal coils inside blood vessels

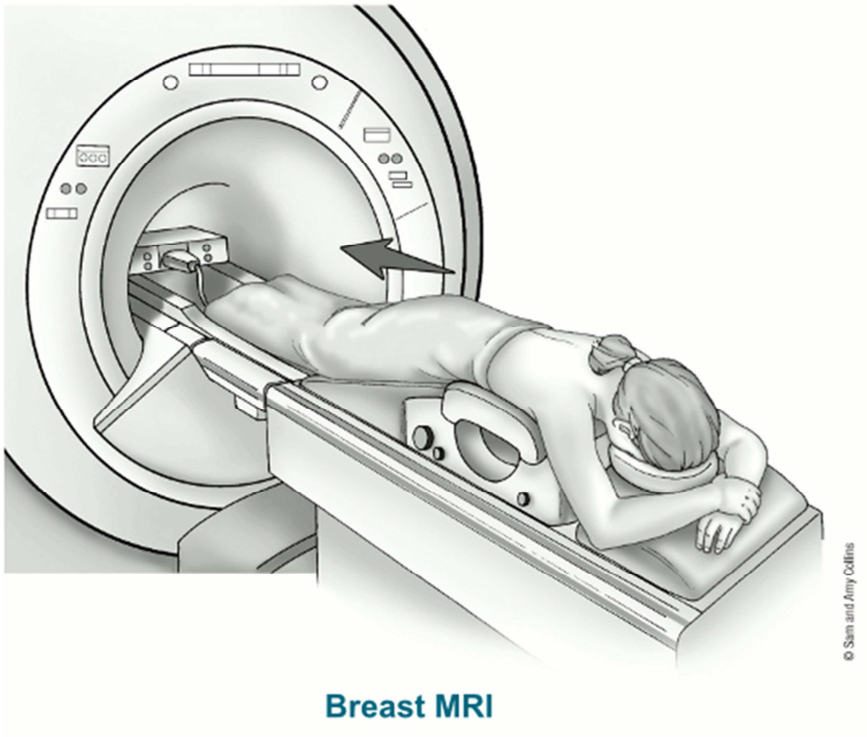

What's it like to get a breast MRI?

MRI scans are usually done on an outpatient basis in a hospital or clinic. You'll lie face down on a narrow, flat table. Your breasts will hang down into an opening in the table so they can be scanned without being compressed. The technologist may use pillows to make you comfortable and help keep you from moving. The table then slides into a long, narrow cylinder.

The test is painless, but you have to lie still inside the narrow cylinder. You may be asked to hold your breath or keep very still during certain parts of the test. The machine may make loud, thumping, clicking, and whirring noises, much like the sound of a washing machine, as the magnet switches on and off. Some facilities give you earplugs or headphones with music to help block noise out during testing.

The most useful MRI exams for breast imaging use a contrast material that's injected into a vein in the arm before or during the exam. This helps to clearly show breast tissue details. The contrast material used for an MRI exam is called gadolinium. (It's not the same as the contrast dye used in CT scans.) Let the technologist know if you have any kind of allergies or have had problems with any contrast or dye used in imaging tests in the past.

It's important to stay very still while the images are being made, which only takes a few minutes at a time. Tell the technologist if you need to move or take a break.

Breast MRI scans can usually take between 45 and 60 minutes. After the test, you may be asked to wait while the pictures are checked to see if more are needed.

Experimental breast imaging tests

Some newer tests are being studied for breast imaging. These tests are in the earliest stages of research. It will take time to see if any are as good as or better than those used today.

Optical imaging tests pass light into the breast and then measure the light that returns or passes through the tissue. The technique does not use radiation and does not require breast compression. Studies going on now are looking at combining optical imaging with other tests like MRI or 3D mammography to help diagnose breast cancer.

Molecular breast imaging (MBI) is a newer nuclear medicine imaging test for the breast. It's being studied as a way to follow up breast problems (such as a lump or an abnormal mammogram). It's also being studied as a test that can be used along with mammograms for women with dense breasts.

Positron Emission Mammography (PEM) is a newly developed imaging exam of the breast. It uses sugar attached to a radioactive particle to detect cancer cells. The PEM scanner is approved by the Food and Drug Administration (FDA). Working much like a PET scan, a PEM scan may be better able to detect small clusters of cancer cells within the breast. Right now it's being studied in women with breast cancer or other breast problems to see if it can show which lumps are cancer.

Electrical impedance imaging (EIT) scans the breast for electrical conductivity. It's based on the idea that breast cancer cells conduct electricity differently from normal cells. The test passes a very small electrical current through the breast and then detects it on the skin of the breast. This is done using small electrodes that are taped to the skin. EIT does not use radiation or compress the breasts. This test is approved by the Food and Drug Administration (FDA) to help classify tumors found on mammograms. But at this time there hasn't had enough clinical testing to use it in breast cancer screening.

References

American Cancer Society. *Breast Cancer Facts and Figures 2013-2014*. Atlanta, Ga: American Cancer Society; 2013.

American College of Radiology. BI-RADS ATLAS – Mammography. Reporting System, 2013. Accessed at www.acr.org/~/media/ACR/Documents/PDF/QualitySafety/Resources/BIRADS/01%20Mammography/02%20%20BIRADS%20Mammography%20Reporting.pdf on June 9, 2014.

American College of Radiology - Radiology Society of North America. Patient Safety: Radiation Exposure in X-ray and CT Examinations. Accessed at www.radiologyinfo.org/en/safety/index.cfm?pg=sfty_xray on December 2, 2013.

Baker L. Breast Cancer Detection Demonstration Project: Five year summary report. *CA Cancer J Clin.* 1982;32:196-229.

Beahrs OH, et al. Report of the working group to review the NCI-ACS Breast Cancer Demonstration Project. *J Natl Cancer Inst*. 1979;62:639-698.

Brown SL, Silverman BG, Berg WA. Rupture of silicone-gel breast implants: causes, sequelae, and diagnosis. *Lancet*. 1997;350:1531-1537.

Bruening W, Uhl S, Fontanarosa J, Reston J, Treadwell J, Schoelles K. Noninvasive Diagnostic Tests for Breast Abnormalities: Update of a 2006 Review [Internet]. Rockville (MD): Agency for Healthcare Research and Quality (US); 2012 Feb. Available from http://www.ncbi.nlm.nih.gov/books/NBK84530/

Caldarella C, Treglia G, Giordano A. Diagnostic performance of dedicated positron emission mammography using fluorine-18-fluorodeoxyglucose in women with suspicious

breast lesions: a meta-analysis. *Clin Breast Cancer*. 2014 Aug;14(4):241-8. Epub 2013 Dec 27.

Fenton JJ, Taplin SH, Carney PA, et al. Influence of computer-aided detection on performance of screening mammography. *N Engl J Med*. 2007;356:1399-1409.

Fitzgerald A, Berentson-Shaw J, New Zealand Guidelines Group. Thermography as a screening and diagnostic tool: a systematic review. *N Z Med J*. 2012;125(1351):80-91.

Freeman MT. Imaging: New techniques. In: Harris JR, Lippman ME, Morrow M, Osborne CK, eds. *Diseases of the Breast*. 4th ed. Philadelphia, Pa: Lippincott Williams & Wilkins; 2010:171-192.

Helvie MA. Imaging analysis: Mammography. In: Harris JR, Lippman ME, Morrow M, Osborne CK, eds. *Diseases of the Breast*. 4th ed. Philadelphia, Pa: Lippincott Williams & Wilkins; 2010:116-130.

Hortobagyi GN, Esserman L, Buchholz TA. Neoplasms of the Breast. In: Hong WK, Bast RC, Hait WN, et al, eds. *Cancer Medicine. 8th ed*. Shelton CT: People's Medical Publishing House – USA/BC Decker; 2010:1393-1459.

Hubbard RA, Kerlikowske K, Flowers CI, et al. Cumulative probability of false-positive recall or biopsy recommendation after 10 years of screening mammography: a cohort study. *Ann Intern Med* 2011;155:481-492.

Kontos M, Wilson R, Fentiman I. Digital infrared thermal imaging (DITI) of breast lesions: sensitivity and specificity of detection of primary breast cancers. *Clin Radiol*. 2011;66(6):536-539.

Osteen RT. Breast cancer. In: Lenhard RE, Osteen RT, Gansler T, eds. *Clinical Oncology*. Atlanta, Ga: American Cancer Society; 2001:251-268.

Pisano ED, Gatsonis C, Hendrick E, et al. Diagnostic performance of digital versus film mammography for breast-cancer screening. *N Engl J Med*. 2005;353:1773-1783.

Povyakalo AA, Alberdi E, Strigini L, Ayton P. How to discriminate between computer-aided and computer-hindered decisions: a case study in mammography. *Med Decis Making*. 2013 Jan;33(1):98-107.

Puliti D, Duffey SW, Miccinesi G, et al. Overdiagnosis in mammographic screening for breast cancer in Europe: a literature review. *J Med Screen*, 2012;19:Suppl 1:42-56.

Rhodes DJ, Hruska CB, Phillips SW, Whaley DH, O'Connor MK. Dedicated dual-head gamma imaging for breast cancer screening in women with mammographically dense breasts. Radiology. 2011 Jan;258(1):106-18. Epub 2010 Nov 2.

Rose SL, Tidwell AL, Bujnoch LJ, et al. Implementation of breast tomosynthesis in a routine screening practice: an observational study. *AJR Am J Roentgenol*. 2013 Jun;200(6):1401-1408.

Rosenberg RD, Hunt WC, Williamson MR, et al. Effects of age, breast density, ethnicity, and estrogen replacement therapy on screening mammographic sensitivity and cancer stage at diagnosis: Review of 183,134 screening mammograms in Albuquerque, New Mexico. *Radiology* 1998; 209:511–518.

Rosenberg RD, Yankaskas BC, Abraham LA, et al. Performance benchmarks for screening mammography. *Radiology*. 2006 Oct;241(1):55-66.

Saslow D, Boetes C, Burke W, et al for the American Cancer Society Breast Cancer Advisory Group. American Cancer Society guidelines for breast screening with MRI as an adjunct to mammography. *CA Cancer J Clin*. 2007;57:75-79.

Skaane P, Bandos AI, Gullien R, et al. Comparison of digital mammography alone and digital mammography plus tomosynthesis in a population-based screening program. *Radiology*. 2013 Apr;267(1):47-56.

Smith RA, D'Orsi C, Newell MS. Screening for breast cancer. In: Harris JR, Lippman ME, Morrow M, Osborne CK, eds. *Diseases of the Breast*. 4th ed. Philadelphia, Pa: Lippincott Williams & Wilkins; 2010:87-115.

Smith RA, Saslow D, Sawyer KA, et al. American Cancer Society guidelines for breast cancer screening: update 2003. *CA Cancer J Clin*. 2003;53:141-169.

Tabar L, Vitak B, Tony HH, et al. Beyond randomized controlled trials: organized mammographic screening substantially reduces breast carcinoma mortality. *Cancer*. 2001;91:1724-1731.

The Radiology Assistant. BI-RADS. Introduction to the Breast Imaging Reporting and Data System, by Harmien Zonderland. Accessed at www.radiologyassistant.nl/en/4349108442109 on December 2, 2013.

Weigert JM, Bertrand ML, Lanzkowsky L, Stern LH, Kieper DA. Results of a multicenter patient registry to determine the clinical impact of breast-specific gamma imaging, a molecular breast imaging technique. *AJR Am J Roentgenol*. 2012 Jan;198(1):W69-75.

Last Medical Review: 12/8/2014
Last Revised: 4/25/2016

2014 Copyright American Cancer Society

For additional assistance please contact your American Cancer Society
1-800-227-2345 or www.cancer.org